


Clinical Insights

SUMMARY OF CLINICAL DATA

MITRACLIP™ TRANSCATHETER MITRAL VALVE REPAIR

HEMODYNAMIC MONITORING DURING MITRACLIP™ PROCEDURES

Early Data, Future Promise



PERSPECTIVE

- MitraClip™ safely and effectively reduces mitral regurgitation (MR) with excellent procedural and clinical outcomes demonstrated in over 100,000 cases world-wide.
- Today, most MitraClip procedures are guided solely by echocardiography which is highly dependent on operator experience (transducer position, acoustic shadows, eccentric jets), and standardized MR assessment post-MitraClip is difficult due to split regurgitant jets.
- Adding intraprocedural hemodynamic monitoring to complement echocardiography/color doppler may help further optimize clip placement and improve clinical outcomes.

KEY HIGHLIGHTS

Hemodynamic monitoring of left atrial pressure (LAP) is an emerging area of interest. Its inclusion can potentially improve post-MitraClip outcomes. When used in combination with echocardiography/color doppler, LAP monitoring facilitates optimal MR reduction while minimizing the risk of iatrogenic stenosis. Importantly, preliminary data has shown continuous LAP monitoring to be:

- An important adjunct to echocardiography/color doppler for guiding clip placement
- Associated with clinically meaningful outcomes: improved heart failure rehospitalizations, symptom status, and exercise capacity
- Feasible in a clinical setting

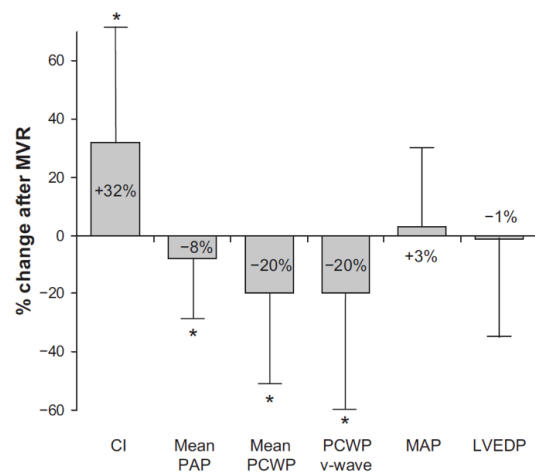
WHY INTRODUCE HEMODYNAMIC MONITORING WITH MITRACLIP?

Hemodynamic monitoring has a well-established role in Transcatheter Aortic Valve Replacement (TAVR) where transaortic pressure is a key index of procedural success. By contrast, reporting of hemodynamic parameters pre-, during, and post-MitraClip is a relatively new practice.

MitraClip placement is conventionally guided by transesophageal echocardiography (TEE) with color doppler imaging (CDI). While effective, both approaches do have limitations. MR defined by vena contracta, PISA, and other TEE measures are not always accurate. Regurgitant jet assessed by CDI is operator-dependent, transducer location-dependent, and lacks standardized quantitative metrics. Jet demarcation by color doppler reflects flow topography rather than the true regurgitant volume, presenting further challenges to interpretation¹.

Importantly, the tissue approximation by the clip reduces MR and also narrows the mitral valve orifice, thereby inducing a risk of elevated transmitral pressure gradients.² Hence, continuous monitoring of LAP during a MitraClip procedure can supplement echocardiography to optimize MR reduction with minimal risk of stenosis².

FIGURE 1: PCWP AND HENCE LAP CHANGES ARE SENSITIVE TO MR CHANGES WITH MITRACLIP³

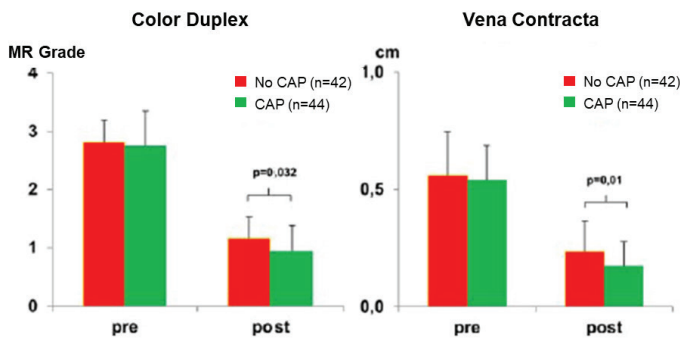


CI, cardiac index; PAP, pulmonary artery pressure; PCWP, pulmonary capillary wedge pressure; MAP mean arterial pressure; LVEDP, left ventricular end diastolic pressure. Source: *Circulation* 2013;127(9):1018-27.

Information herein for **DISTRIBUTION outside of the U.S. ONLY**. Always check the regulatory status of the device in your region.



FIGURE 2: CONTINUOUS LAP WITH ECHOCARDIOGRAPHY



Continuous LAP with echocardiography reduced MR grade and Vena Contracta after MitraClip compared to only echocardiography. Source: *Catheterization and Cardiovascular Interventions* 2016;88(7):1134–43.

DOES CONTINUOUS LAP MONITORING HAVE A CLINICALLY MEANINGFUL IMPACT?

Early observational studies showed improvement in multiple hemodynamic parameters following MitraClip, specifically pulmonary capillary wedge pressure, a surrogate of LAP [FIGURE 1]^{3,4}. Subsequent studies reported improved clinical outcomes with continuous LAP monitoring:

- **Lower post-procedural regurgitation, without a significant increase in procedural duration or complication rate [FIGURE 2]⁵**

In a study of 86 patients undergoing MitraClip, continuous LAP monitoring (CAP, n=44) was compared with intermittent measurement (n=42). A greater reduction in MR grade was observed in the group who underwent CAP compared to the intermittent measurement group (2.8→0.9 vs. 2.8→1.3, p=0.03) which persisted through discharge.

- **Improved exercise tolerance assessed by six minute walk distance (6MWD [FIGURES 3 AND 4]⁶**

In a single center study of 50 patients, change in LAP v-wave was independently associated with longer 6MWD and improved New York Heart Association (NYHA) class at 30 days. Additionally, each 5 mmHg decrease in mean V-wave was associated with a 49% increase in the likelihood of improved 6MWD (OR=1.49, 95% CI: 1.01-2.18, p=0.04). Patients with V-wave drop of > 11 mmHg (median) were 3.8x more likely to improve their 6MWD (p=0.05)

- **Reduced heart failure rehospitalization (HFH) and NYHA III/IV [FIGURE 5]⁷**

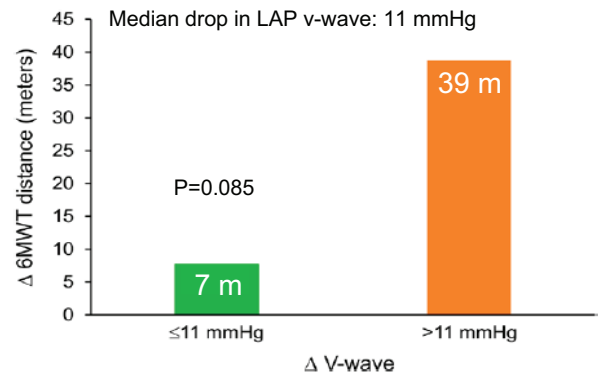
In a sub-study of 50 patients from the MitraSwiss registry, higher indexed mean LAP (LAMPi, mean LAP adjusted to LV systolic pressure) was associated with

- re-hospitalization for heart failure [FIGURE 5] (log rank p=0.001), and
- worsening NYHA III/IV (multivariate HR 1.5, 95%CI 1.01-2.10, p=0.005)

Residual MR by doppler echo failed to show these relationships, further supporting the adjunctive value of hemodynamics in deciding clip placement and/or repositioning.

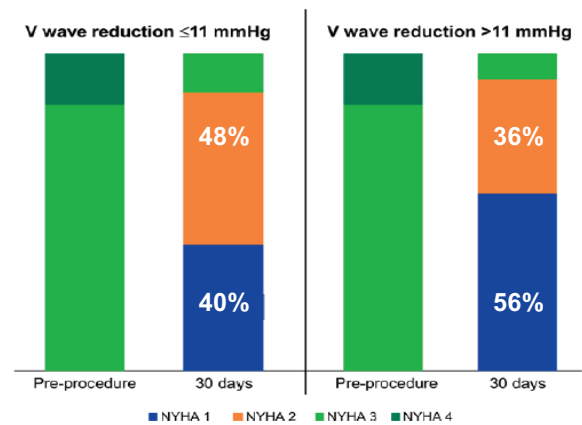
Information herein for **DISTRIBUTION outside of the U.S. ONLY**. Always check the regulatory status of the device in your region.

FIGURE 3: 6MW TEST – PATIENTS WITH LAP V-WAVE DECREASE



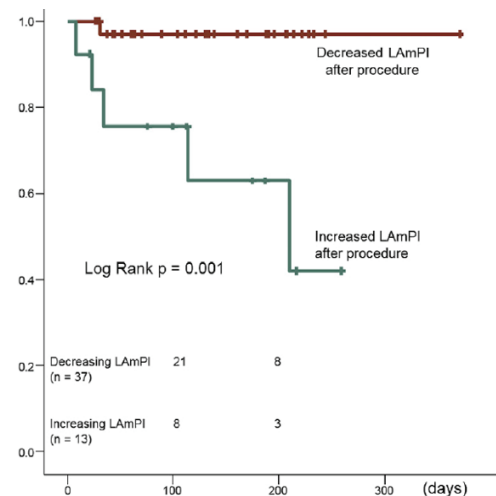
In the 6MW test, patients with a LAP v-wave decrease > 11 mmHg could walk substantially further after receiving a MitraClip than those with < 11 mmHg change. Source: *Cardiovascular Interventions* 2017;10(4):e004856.

FIGURE 4: PATIENTS WITH LAP V-WAVE DECREASE



Patients with a LAP v-wave decrease > 11 mmHg had a higher proportion of NYHA I/II after MitraClip compared to those with < 11 mmHg change. Source: *Cardiovascular Interventions* 2017;10(4):e004856.

FIGURE 5: HEART FAILURE REHOSPITALIZATION



Freedom from heart failure rehospitalization is statistically associated with a decrease in the indexed mean left atrial pressure (LAMPi). Source: *JACC: Cardiovascular Interventions* 2019;12(2):127–36.

HOW IS INTRAPROCEDURAL LAP MONITORING DONE AND IS IT FEASIBLE IN A CLINICAL SETTING?

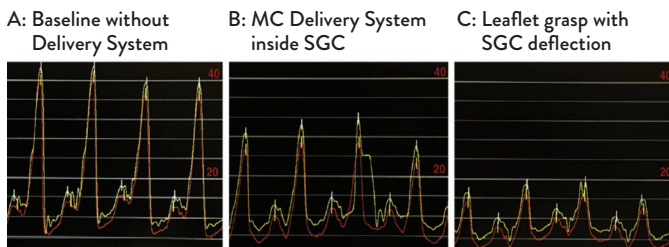
Pulmonary capillary wedge pressure (PCWP) is frequently used as an indirect surrogate for LAP, and has a well-established prognostic role in mitral stenosis⁸, heart failure and mitral regurgitation⁹. In healthy states, the LAP and PCWP are well correlated ($r=0.95$)¹⁰. However in mitral regurgitation, the correlation is less evident ($r=0.79$)¹¹.

Instead, direct LAP measurements are more accurate and is thus preferable to guide clip implantations.

LAP can be measured using a separate (buddy) catheter delivered transseptally to the left atrium but this approach increases complexity, risks, and procedural time¹². Instead, some users continuously transduced LAP through the steerable guide catheter (SGC) of the original MitraClip and the MitraClip NT and NTR/XTR systems. Flow inhibition within the SGC by the MitraClip delivery catheter (CDS) during clip placement can create problems.

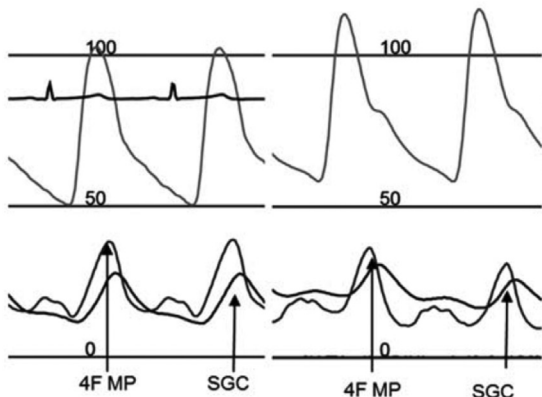
When blood flow in the SGC is unimpeded, continuous monitoring occurs [FIGURE 6]¹³ but the SGC waveforms are overdamped compared to those obtained with the buddy catheter [FIGURE 7]¹². When flow is insufficient, the signal is sporadic, overdamped, or drops off completely especially when the CDS rotates down to cross the mitral valve^{2,12}. A redesign of the SGC in the next generation MitraClip G4 will mitigate these issues and enable continuous tracking of the LAP with accuracy and consistency.

FIGURE 6: LEFT ATRIAL PRESSURE TRACINGS¹³



Consistency and reproducibility of left atrial pressure tracings transduced from the side-hole buddy catheter (red line) and via the SGC (yellow line) at key stages of the MitraClip procedure (5 cases). Mean and maximum observed difference in mean LA pressure between the SGC and side-hole catheter were 1.3 and 3.0 mm Hg, respectively. **Source: JACC: Cardiovascular Interventions 2017;10(14):1466-7**

FIGURE 7: THE SGC LAP WAVEFORM¹²



The SGC LAP waveform (SGC) is overdamped and slightly lagging that from a dedicated pigtail catheter (4F MP). **Source: Catheterization and Cardiovascular Interventions 2018;92(2):374-8.**

SUMMARY

- Adjunctive continuous LAP monitoring with standard color doppler imaging provides important objective data for proceduralists to optimize MR reduction while minimizing risks for iatrogenic mitral stenosis during MitraClip placement
- Continuous LAP monitoring has the potential to positively impact clinical outcomes by reducing heart failure rehospitalization, improving functional symptoms, and increasing exercise capacity.
- Continuous LAP monitoring is feasible clinically, though the promising early data will need to be confirmed in larger studies to establish optimal monitoring criteria.

REFERENCES

1. Lin BA, Forouhar AS, Pahlevan NM, et al. Color Doppler Jet Area Overestimates Regurgitant Volume when Multiple Jets are Present. *J Am Soc Echocardiogr* 2010;23(9):993-1000.
2. Tang GHL, Ong LY, Kaple R, et al. Continuous invasive hemodynamic monitoring using steerable guide catheter to optimize mitral clip transcatheter mitral valve repair: A multicenter, proof-of-concept study. *J Intervent Cardiol* 2018;31(6):907-15.
3. Gaemperli O, Moccetti M, Surder D, et al. Acute haemodynamic changes after percutaneous mitral valve repair: relation to mid-term outcomes. *Heart* 2012;98(2):126-32.
4. Gaemperli Oliver, Biaggi Patric, Gugelmann Remo, et al. Real-Time Left Ventricular Pressure-Volume Loops During Percutaneous Mitral Valve Repair With the MitraClip System. *Circulation* 2013;127(9):1018-27.
5. Horstkotte J, Kloeser C, Beucher H, Schwarzlaender E, Bardeleben RS von, Boekstegers P. Intraoperative assessment of mitral regurgitation during the mitral clip procedure: Impact of continuous left atrial pressure monitoring. *Catheter Cardiovasc Interv* 2016;88(7):1134-43.
6. Maor Elad, Raphael Claire E., Panaich Sidakpal S., et al. Acute Changes in Left Atrial Pressure After MitraClip Are Associated With Improvement in 6-Minute Walk Distance. *Circ Cardiovasc Interv* 2017;10(4):e004856.
7. Kuwata S, Taramasso M, Czopak A, et al. Continuous Direct Left Atrial Pressure: Intraoperative Measurement Predicts Clinical Response Following MitraClip Therapy. *JACC Cardiovasc Interv* 2019;12(2):127-36.
8. Nagy AI, Venkateshvaran A, Dash PK, et al. The pulmonary capillary wedge pressure accurately reflects both normal and elevated left atrial pressure. *Am Heart J* 2014;167(6):876-83.
9. Ritzema Jay, Melton Iain C., Richards A. Mark, et al. Direct Left Atrial Pressure Monitoring in Ambulatory Heart Failure Patients. *Circulation* 2007;116(25):2952-9.
10. Walston A, Kendall ME. Comparison of pulmonary wedge and left atrial pressure in man. *Am Heart J* 1973;86(2):159-64.
11. Chen L, Mantri N, Eng ML, et al. Intraoperative direct left atrial and wedge pressure correlation during transcatheter mitral valve repair: Results from a single center registry. *Catheter Cardiovasc Interv Off J Soc Card Angiogr Interv* 2019;94(1):165-70.
12. Eleid MF, Reeder GS, Rihal CS. Comparison of left atrial pressure monitoring with dedicated catheter versus steerable guiding catheter during transcatheter mitral valve repair. *Catheter Cardiovasc Interv* 2018;92(2):374-8.
13. Gajjar M, Yadlapati A, Van Assche, LMR, et al. Real-Time Continuous Left Atrial Pressure Monitoring During Mitral Valve Repair Using the MitraClip NT System. *JACC Card. Interv* 2017;10(14):1466-67.

CAUTION: This product is intended for use by or under the direction of a physician. Prior to use, reference the Instructions for Use, inside the product carton (when available) or at eifu.abbottvascular.com or at medical.abbott/manuals for more detailed information on Indications, Contraindications, Warnings, Precautions and Adverse Events. Information contained herein for **DISTRIBUTION outside of the U.S. ONLY**. Always check the regulatory status of the device in your region.

Illustrations are artist's representations only and should not be considered as engineering drawings or photographs. Photos on file at Abbott.

Abbott 3200 Lakeside Dr., Santa Clara, CA. 95054 USA, Tel: 1.800.227.9902

™ Indicates a trademark of the Abbott group of companies. www.Cardiovascular.Abbott
©2020 Abbott. All rights reserved.
MAT-2002371 v1.0 | Item approved for Global OUS use only.

